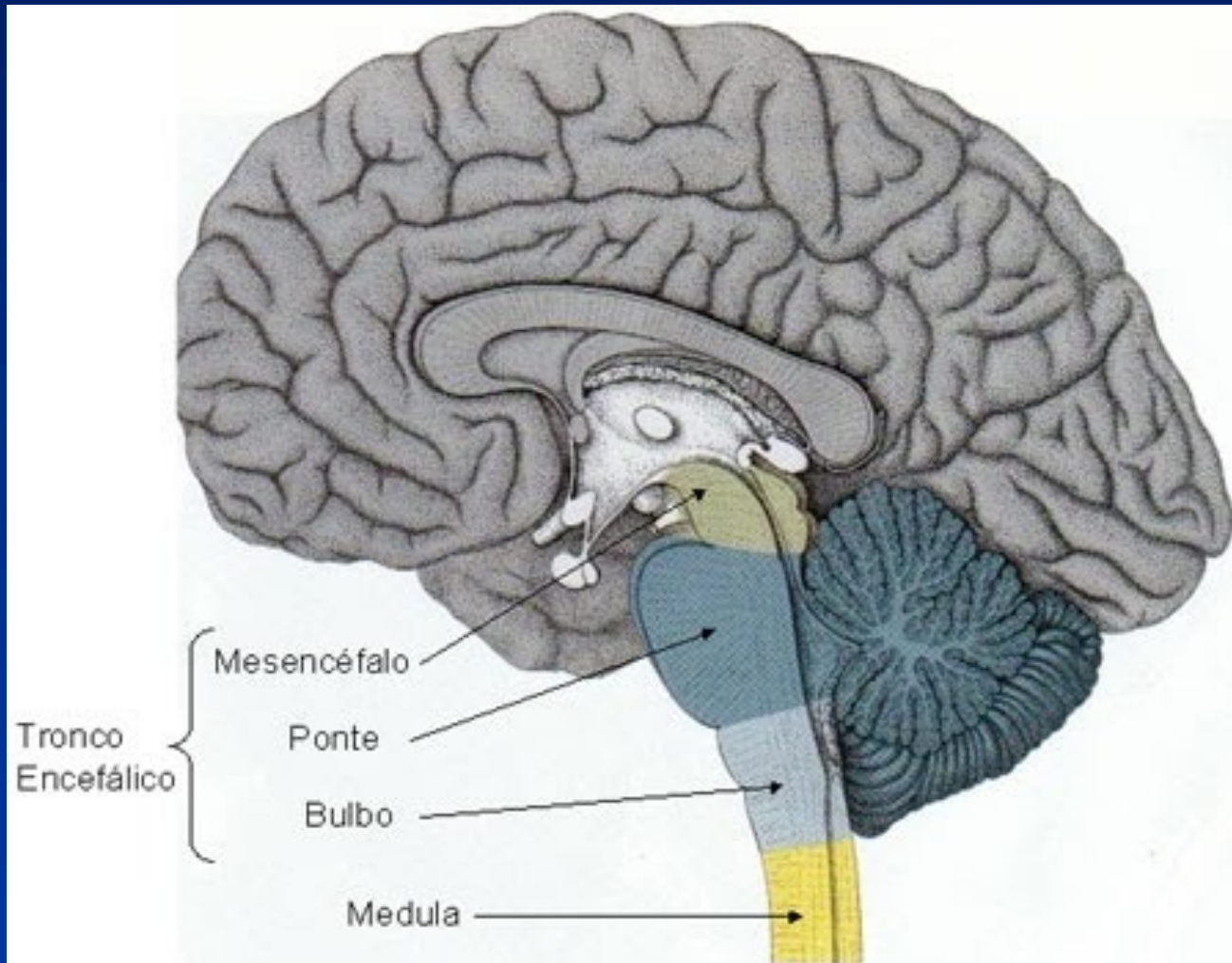


# **NERVOS CRANIANOS**

# TRONCO ENCEFÁLICO



MESENCÉFALO

3°

~~4°~~

Medial  
Longitudinal  
Fasciculus

PONTE

6°

5°

7°

8°

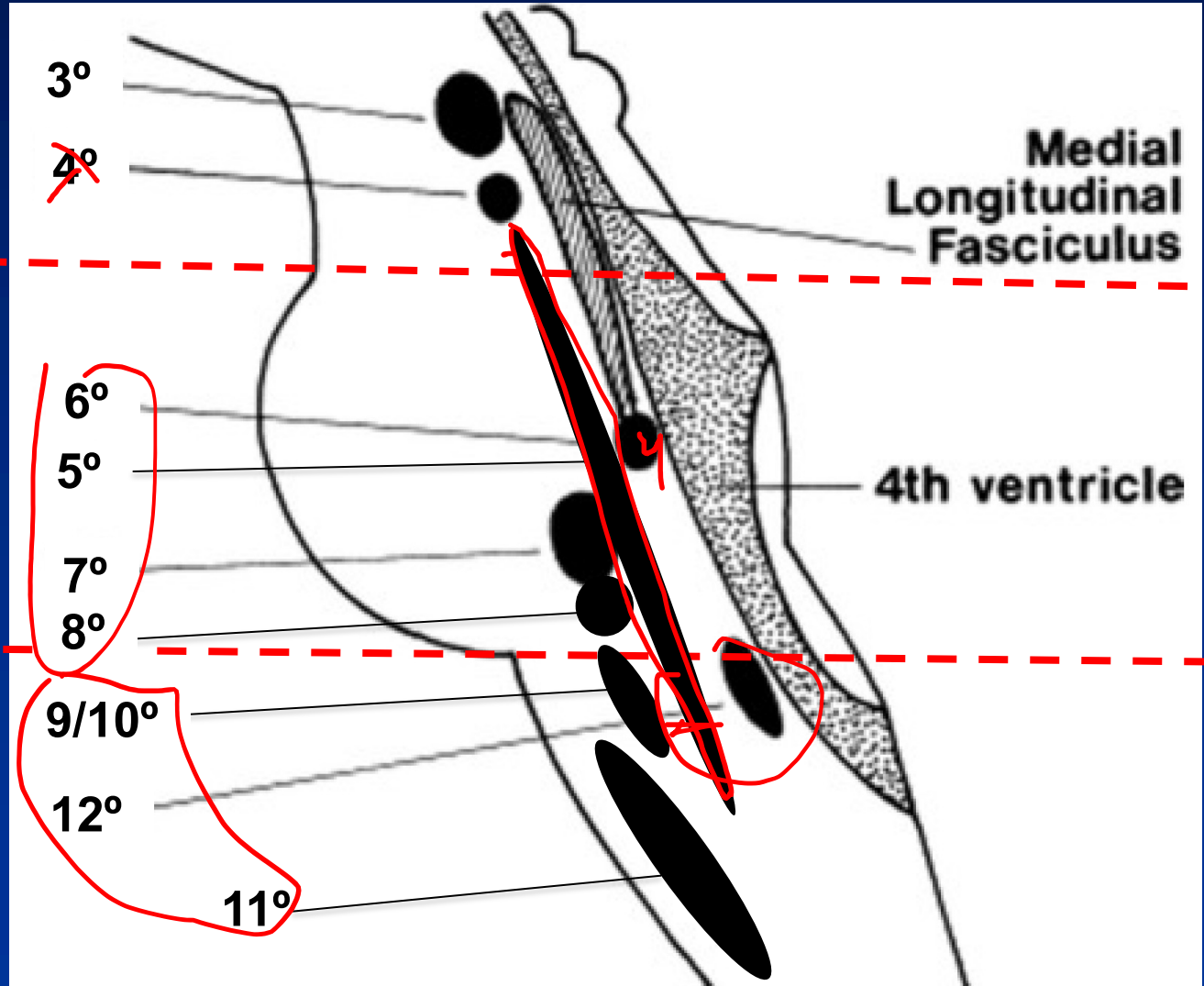
4th ventricle

BULBO

9/10°

12°

11°



1º

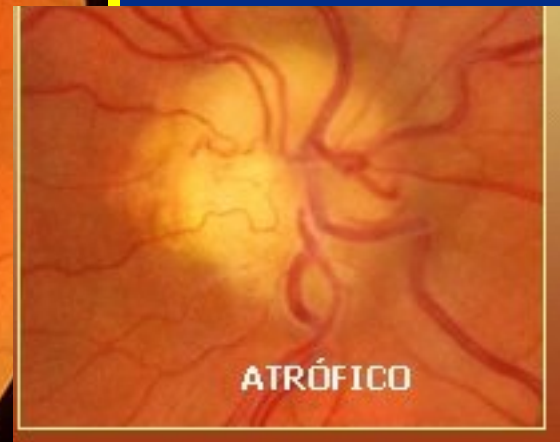
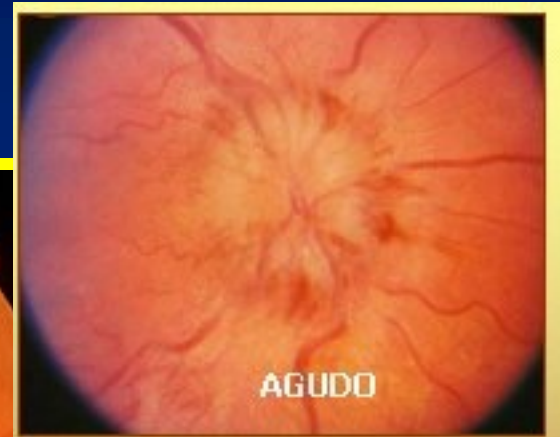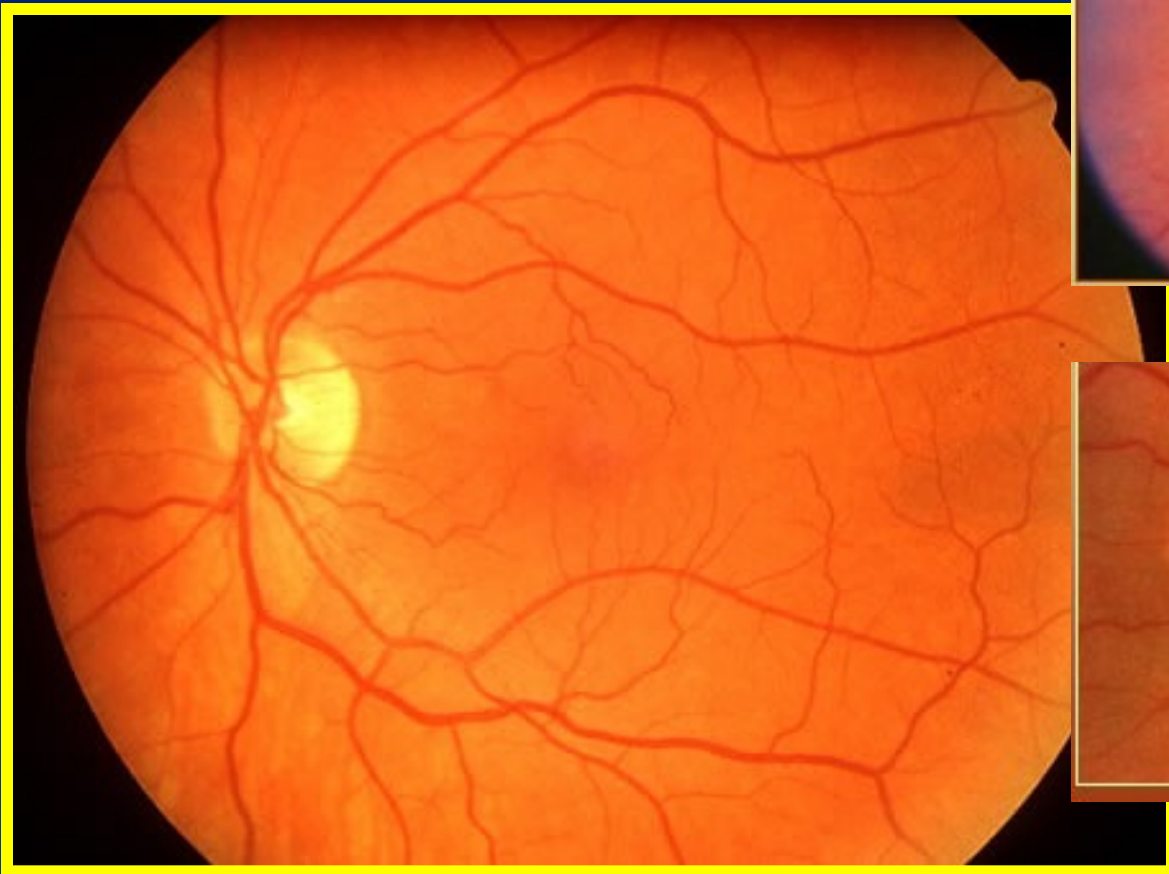
Nat Rev Neurol. 2012 May 15;8(6):329-39. doi: 10.1038/nrneurol.2012.80.

## **Disfunção olfatória na doença de Parkinson**

Doty RL.



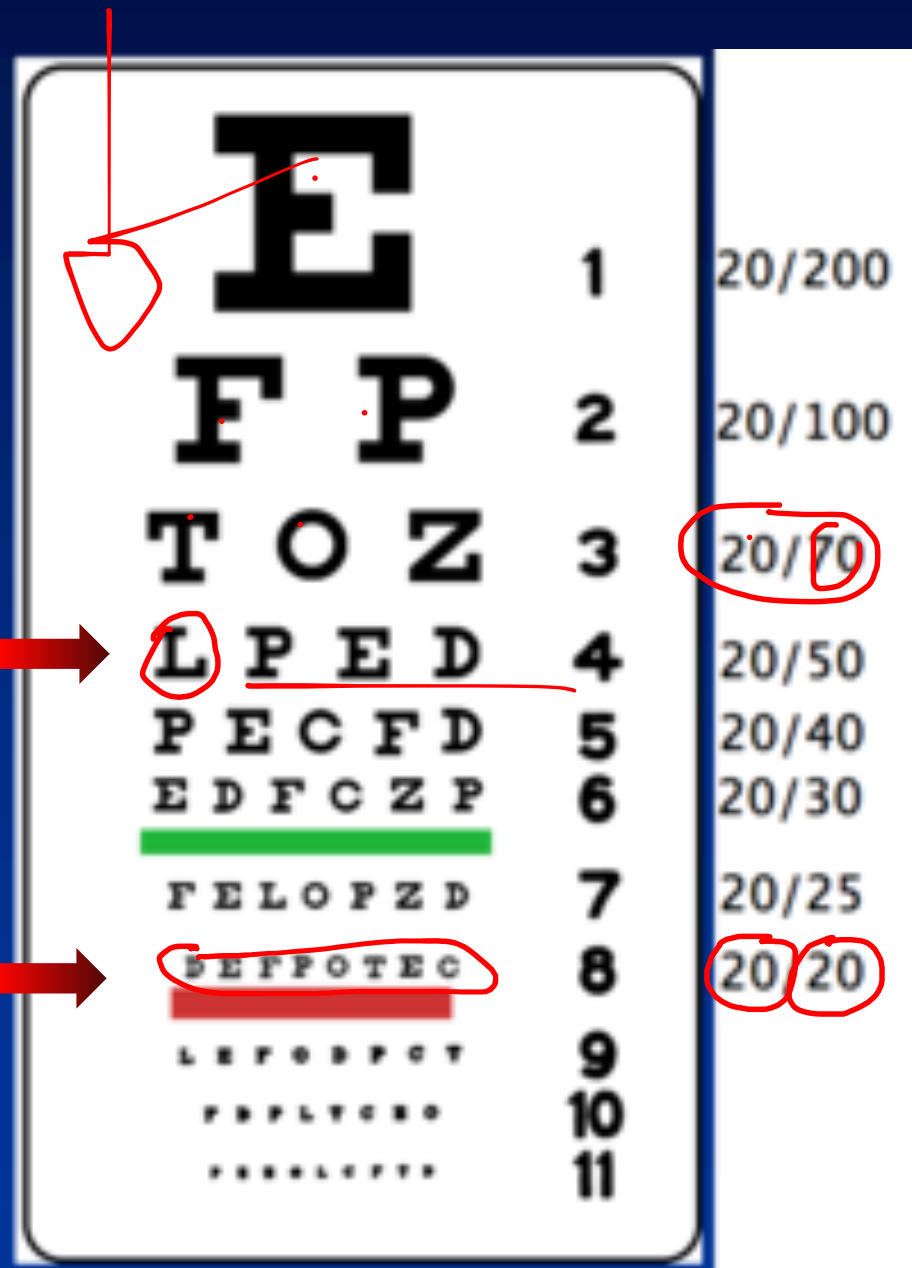
2º



# Snellen

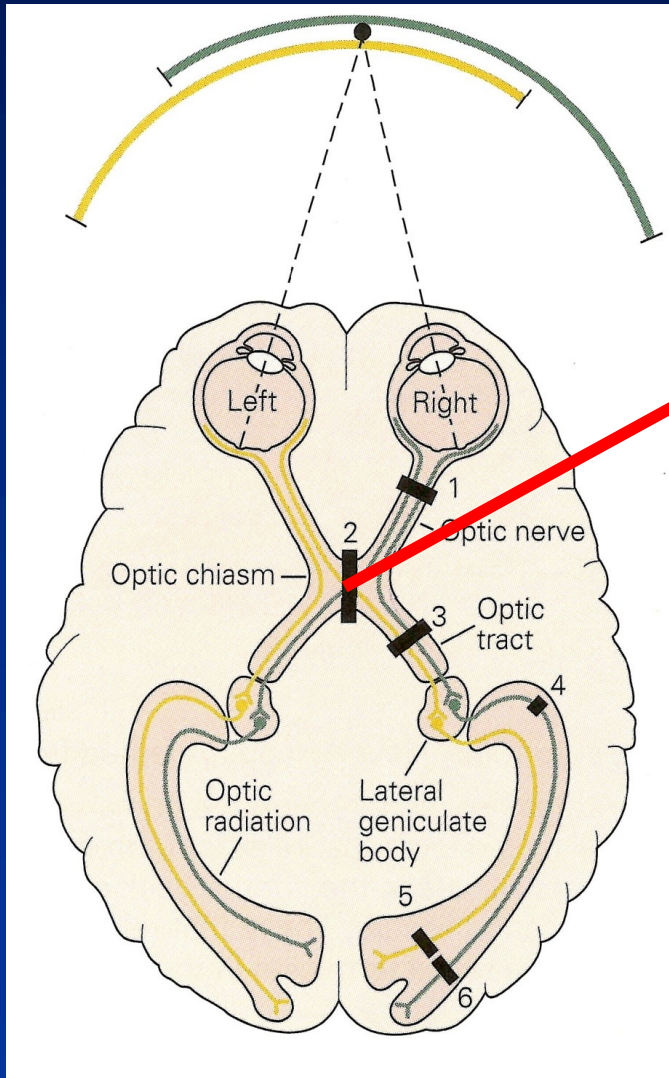
Pte lê à 20 pés o  
que uma pessoa  
normal leria à 50.

Normal



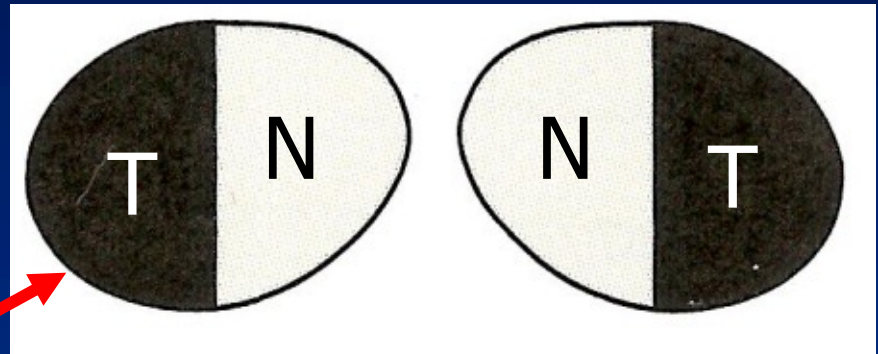


**CAMPIMETRIA**



Olho esquerdo


Olho direito

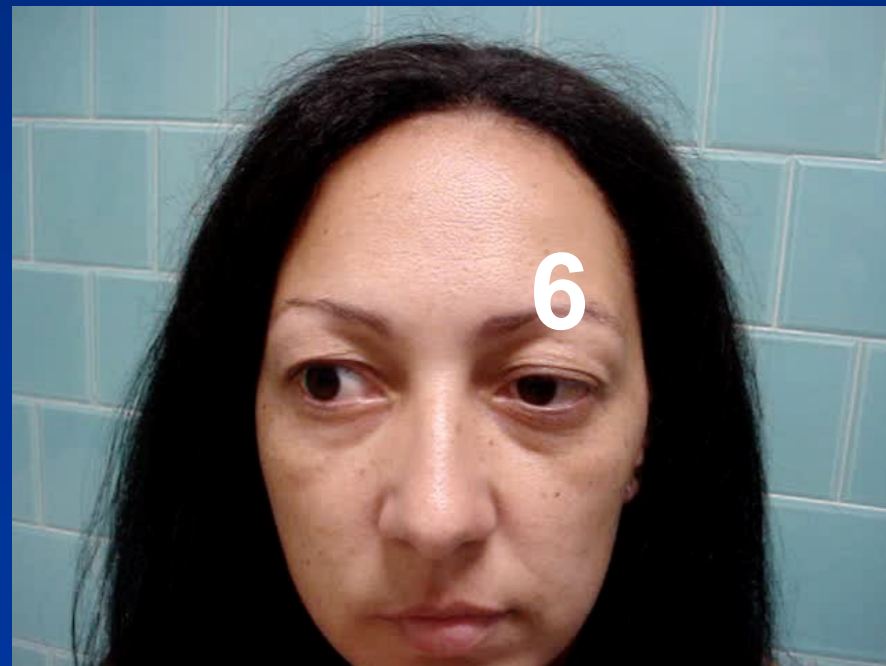
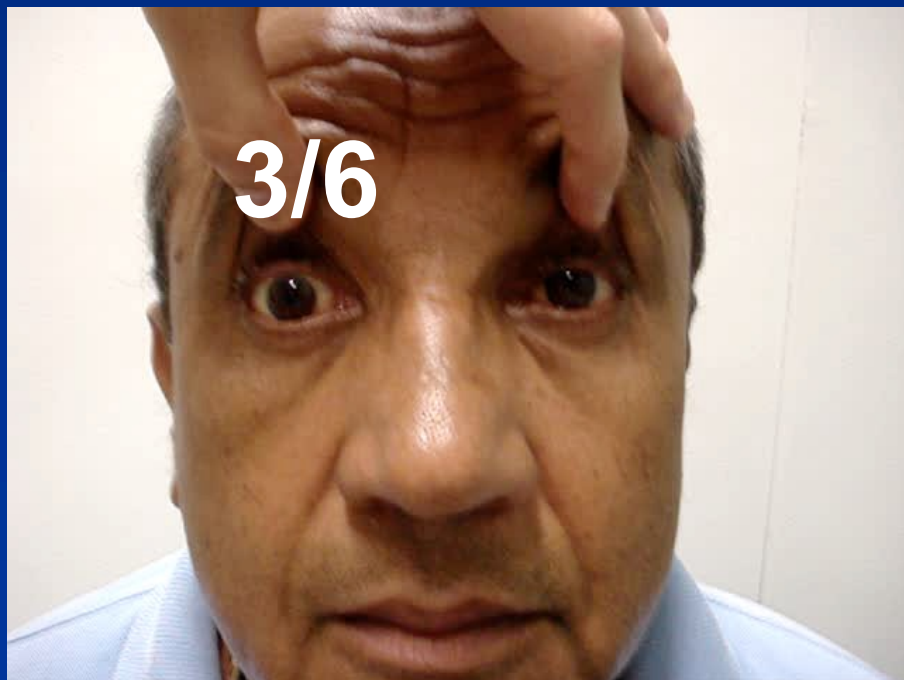
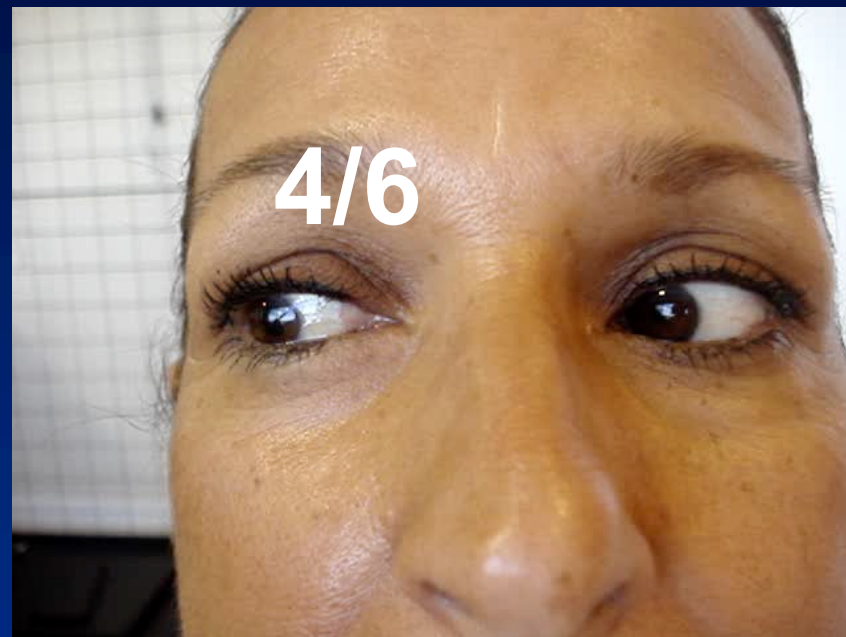
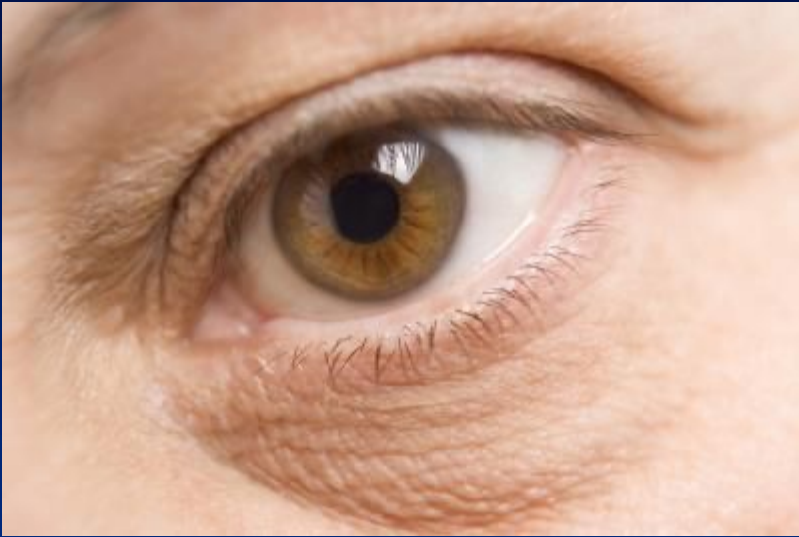
**CAMPIMETRIA**



3° - 4° - 6°





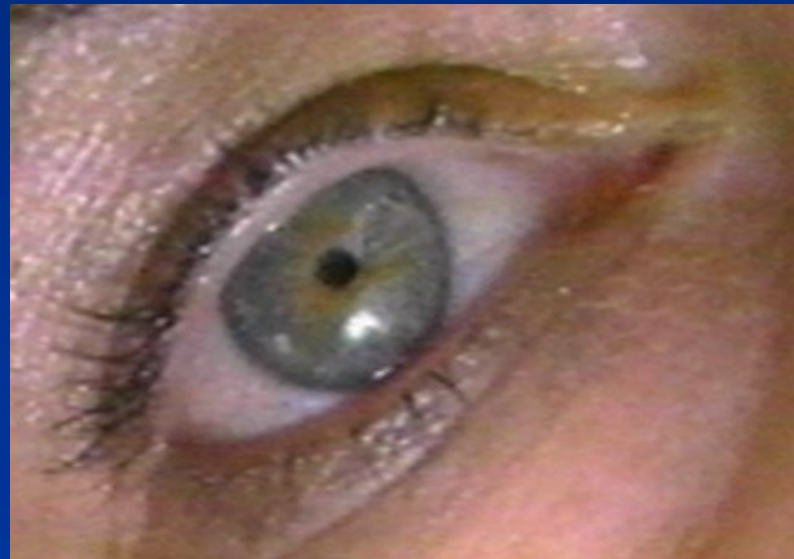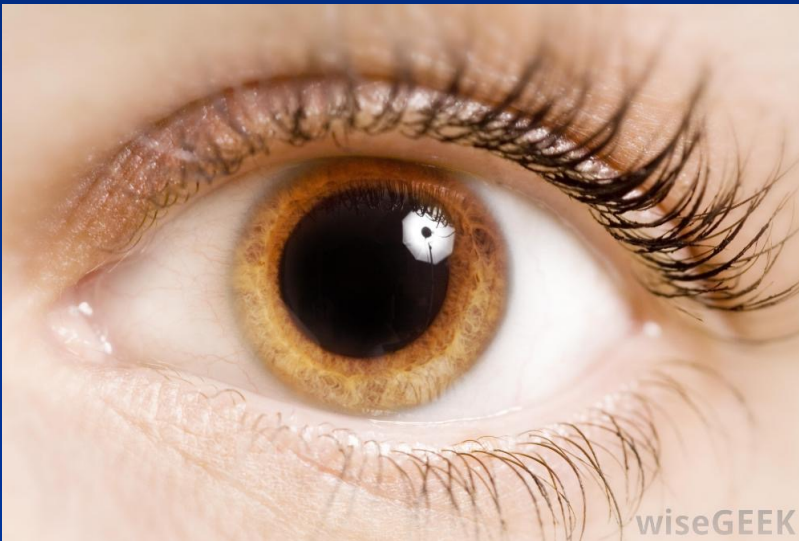


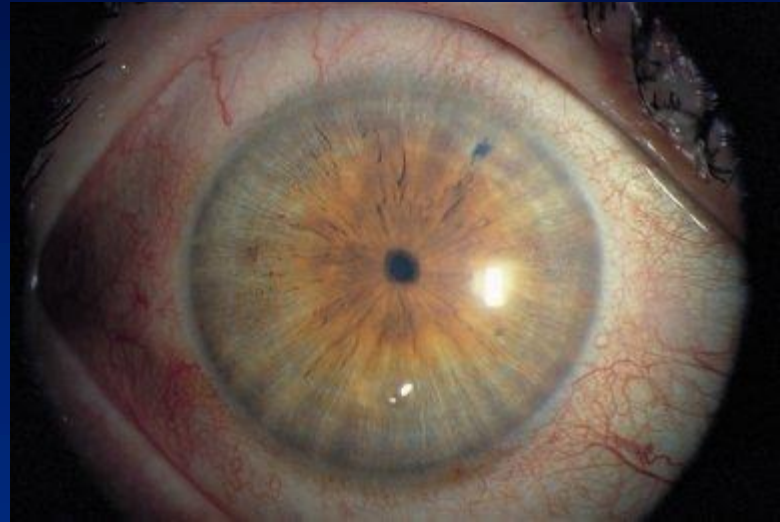**Normal**

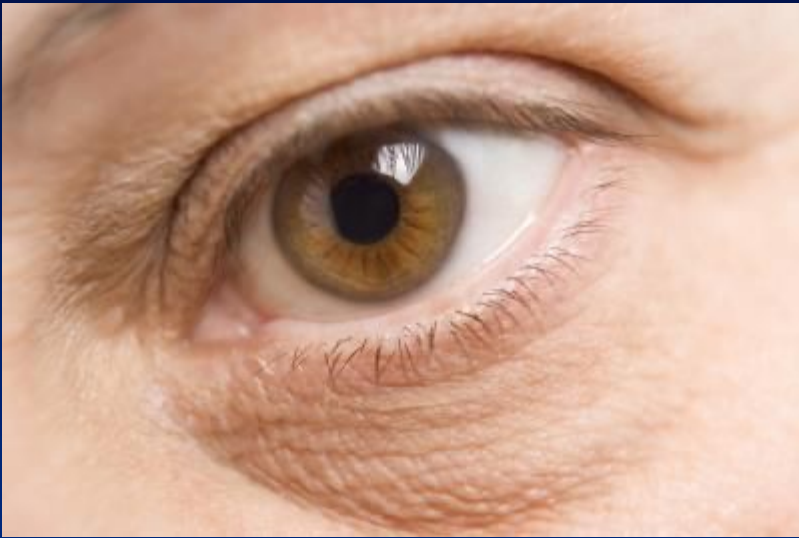



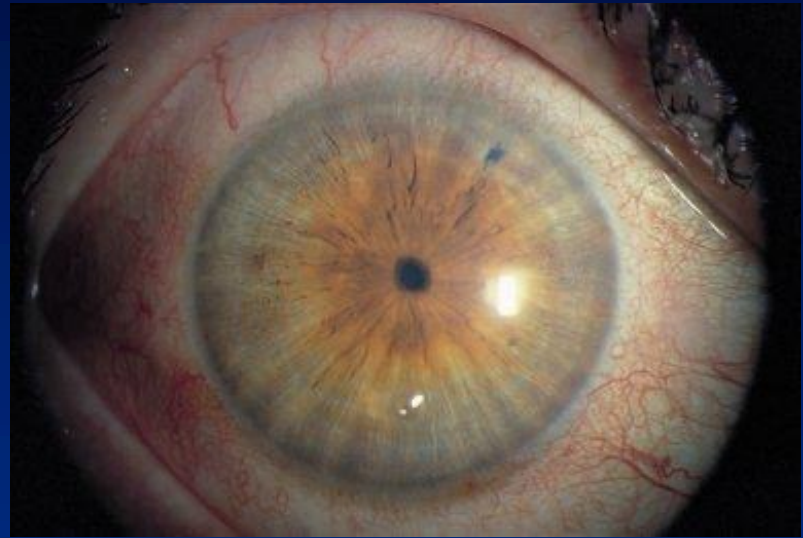
**Normal**



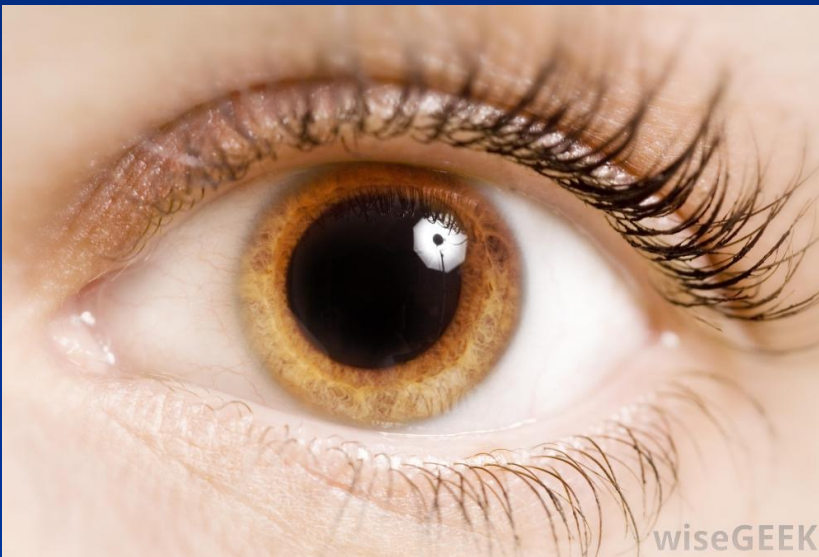



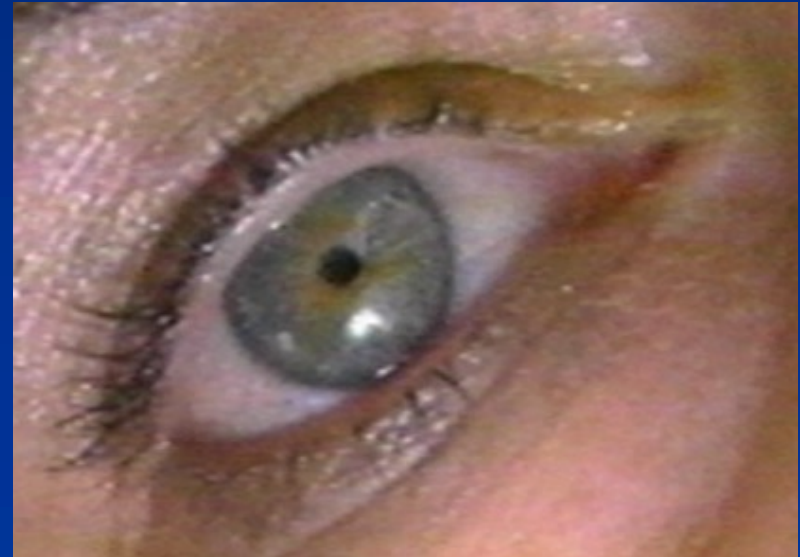**Normal**



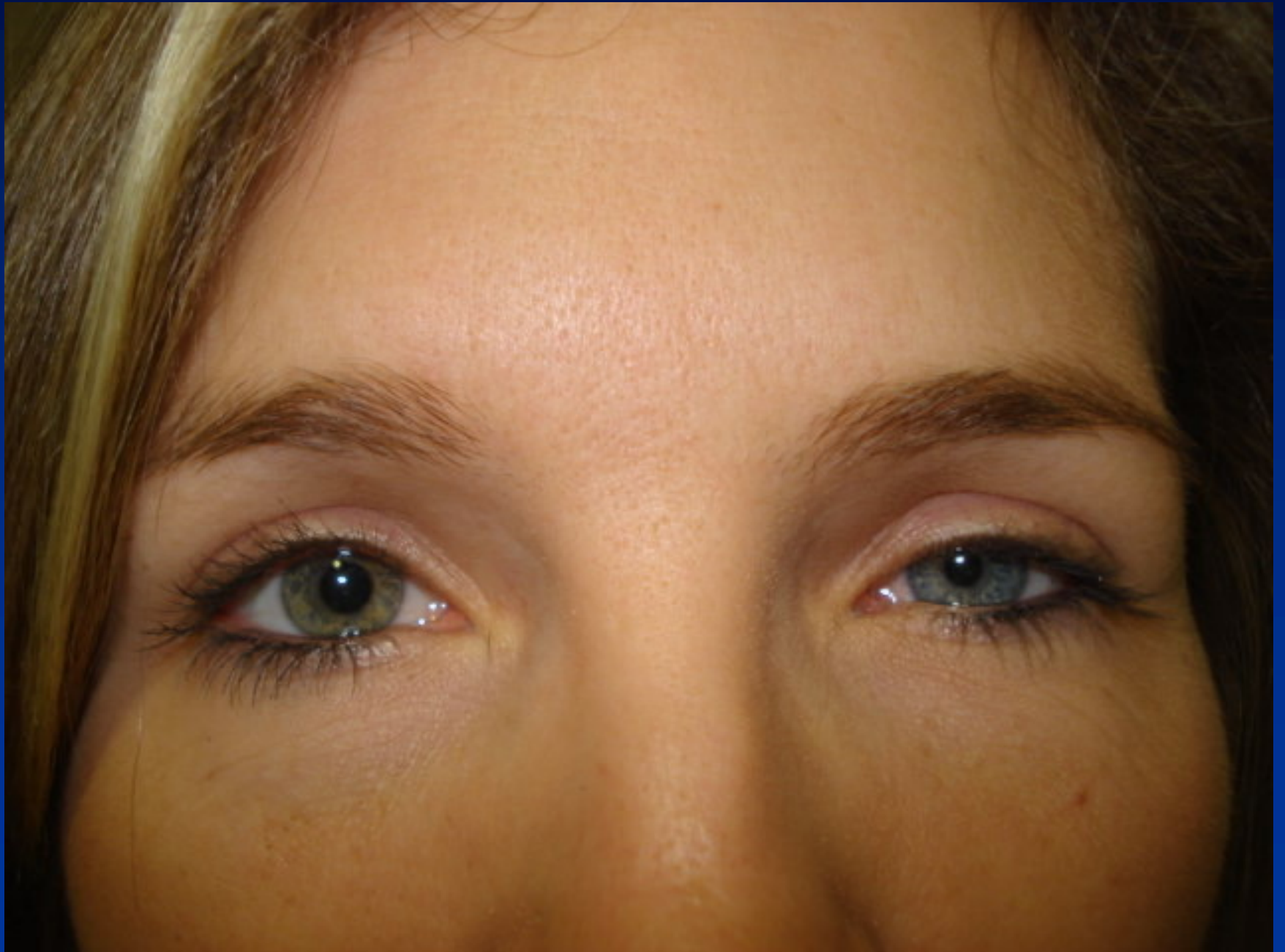**Lesão pontina**

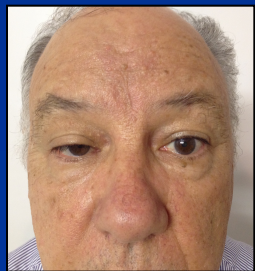
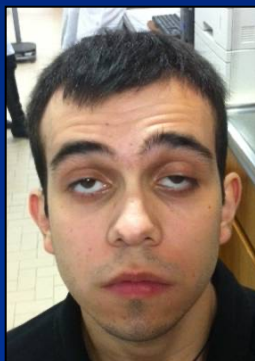
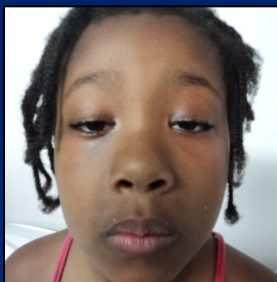
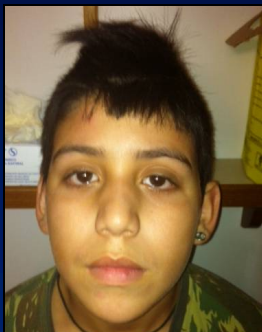

**Lesão mesencefálica**



**Intoxicação opióide**





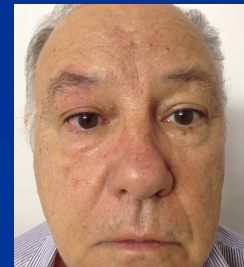
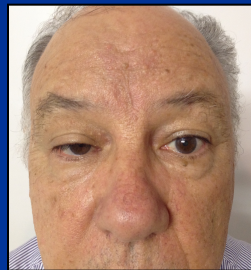
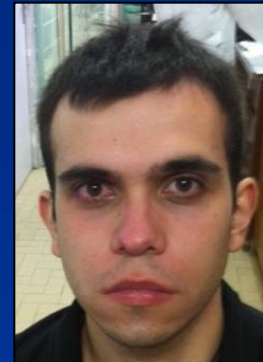
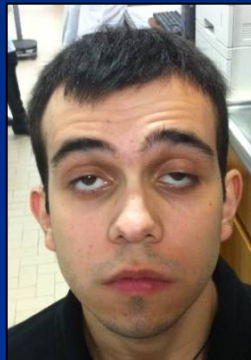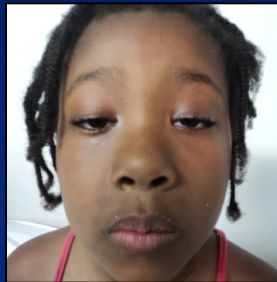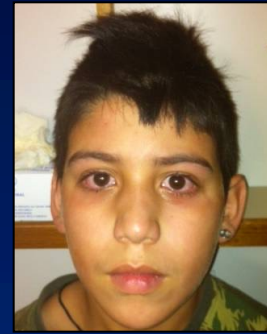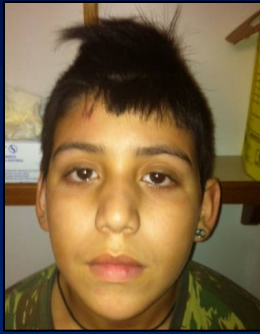Neurologia HCPA (consentimento informado)

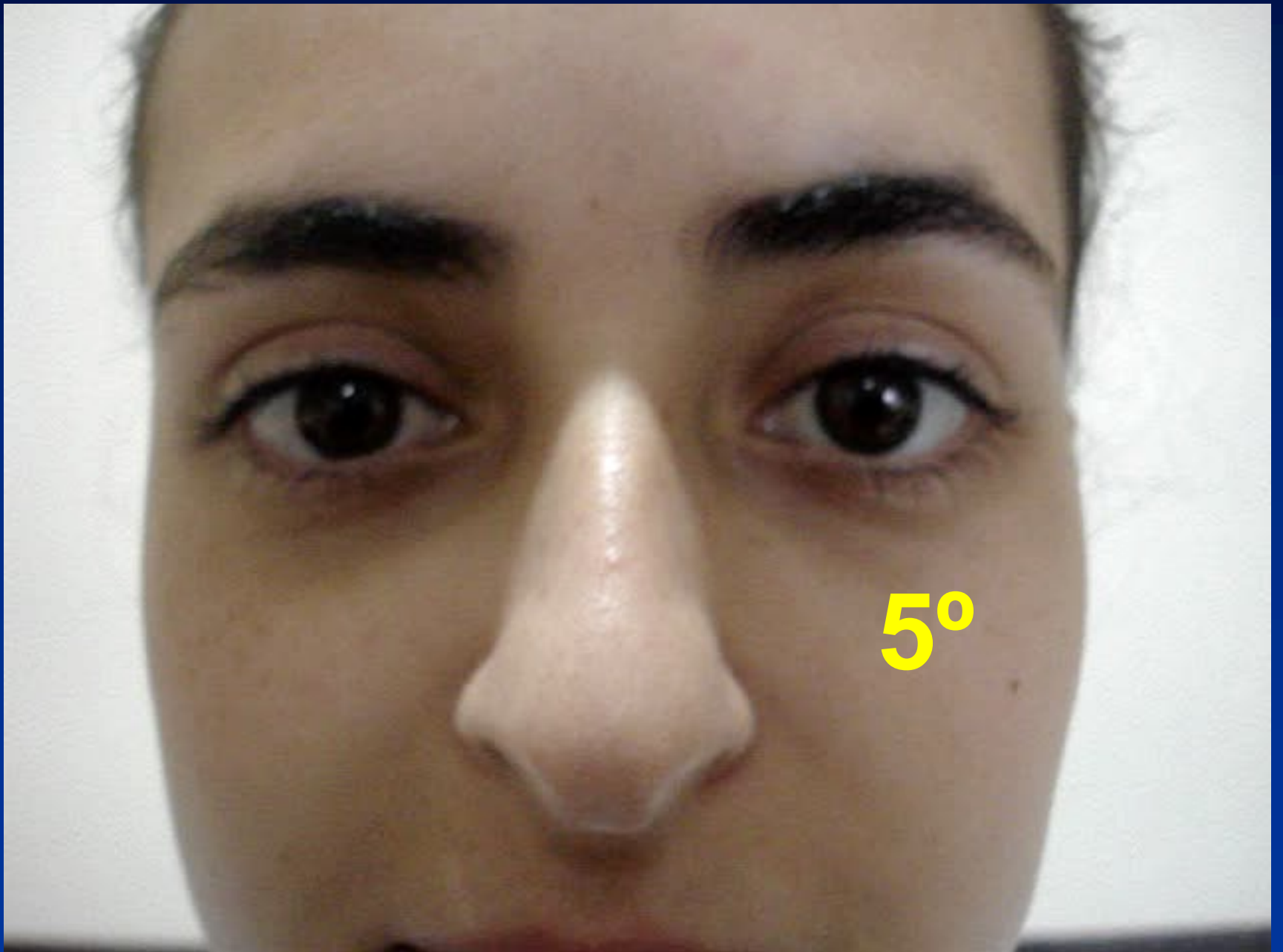


# Ice Test

S = 92%

E = 88%





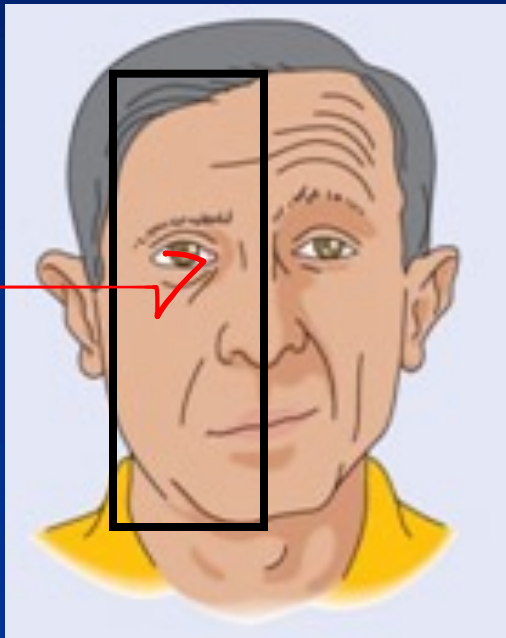
# 7º

Onde está a anormalidade facial?

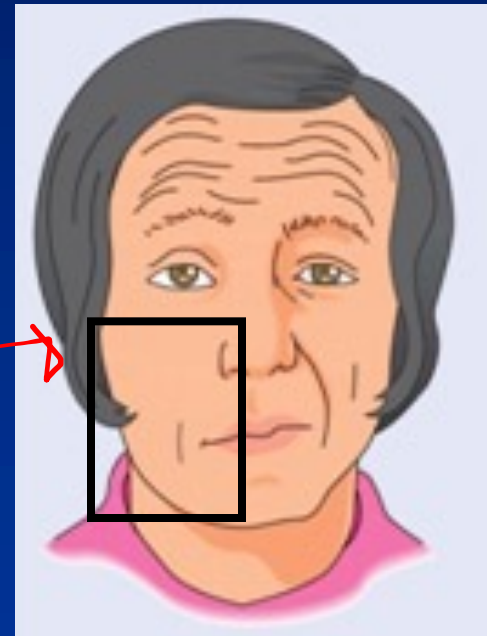


# 7º

Onde está a anormalidade facial?




**Toda hemiface**  
**- Periférico**



**Hemiface inferior**  
**- Central**

## Parálisis de Bell (periférica): de que lado?





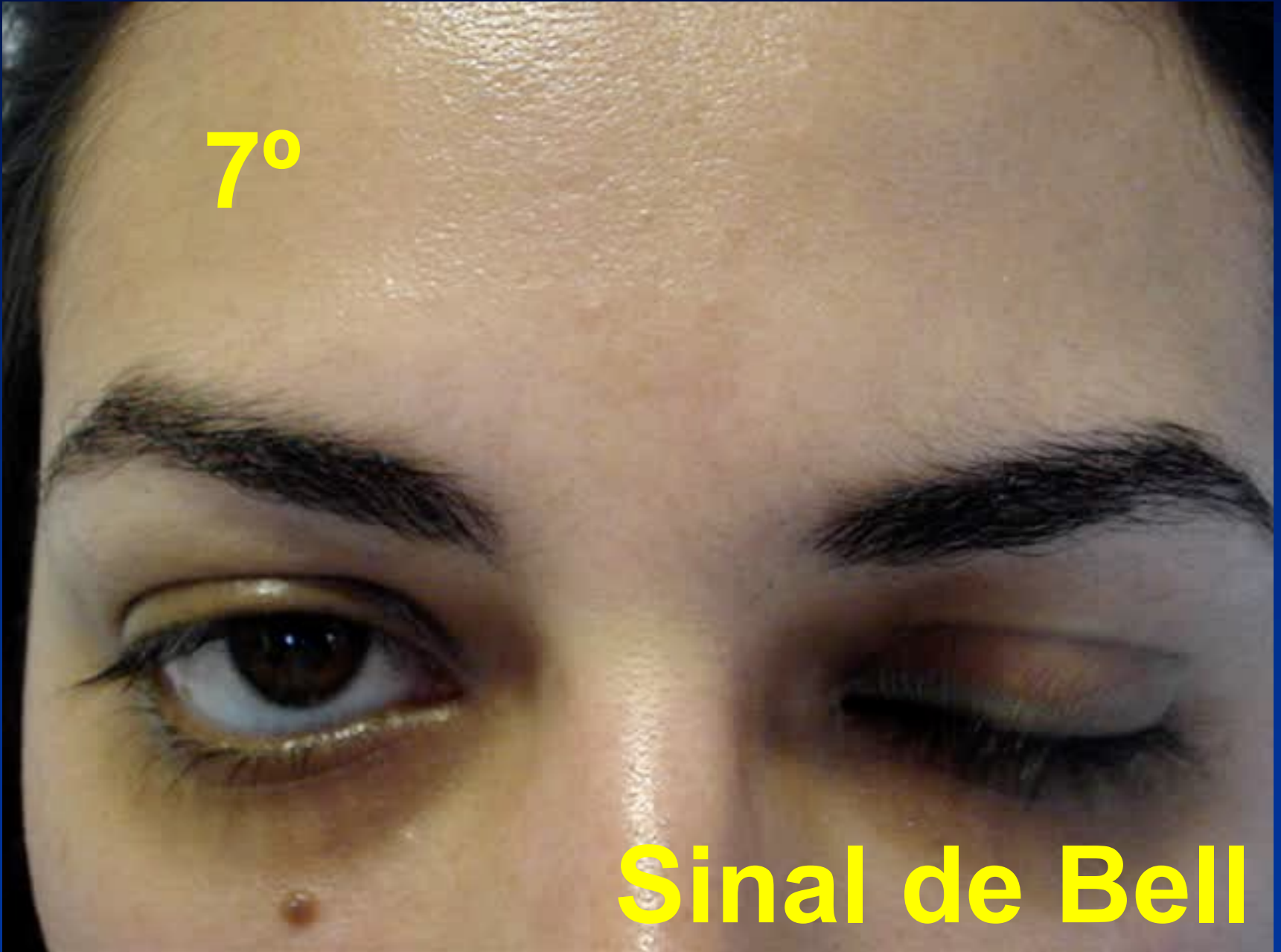# Paralísia de Bell (periférica): de que lado?

7º



7°

**Sinal de Bell**



8º

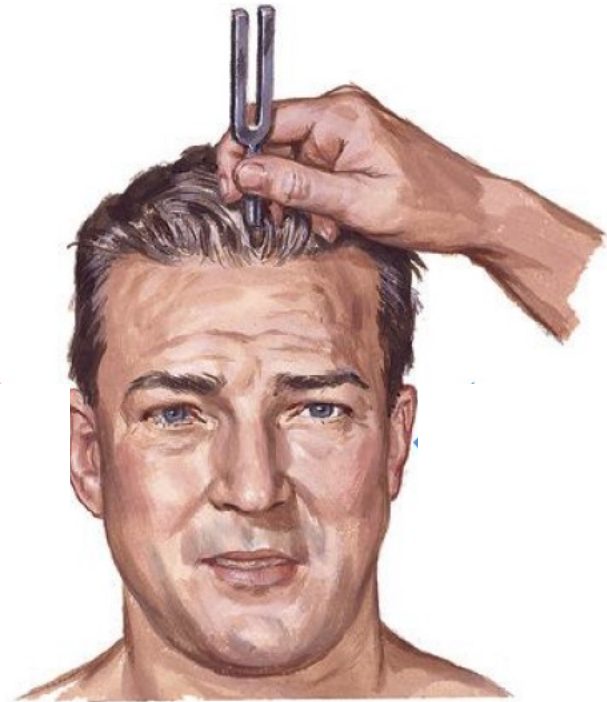
**Teste de acuidade auditiva**

**Se alterado: fazer as  
manobras a seguir**

8º

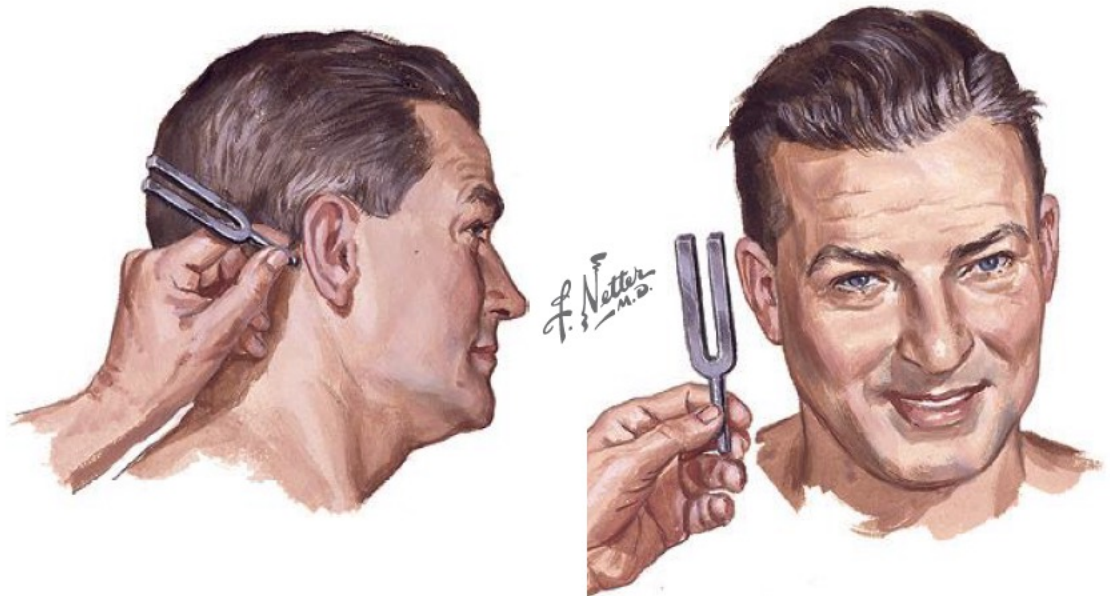
# WEBER

Não lateraliza



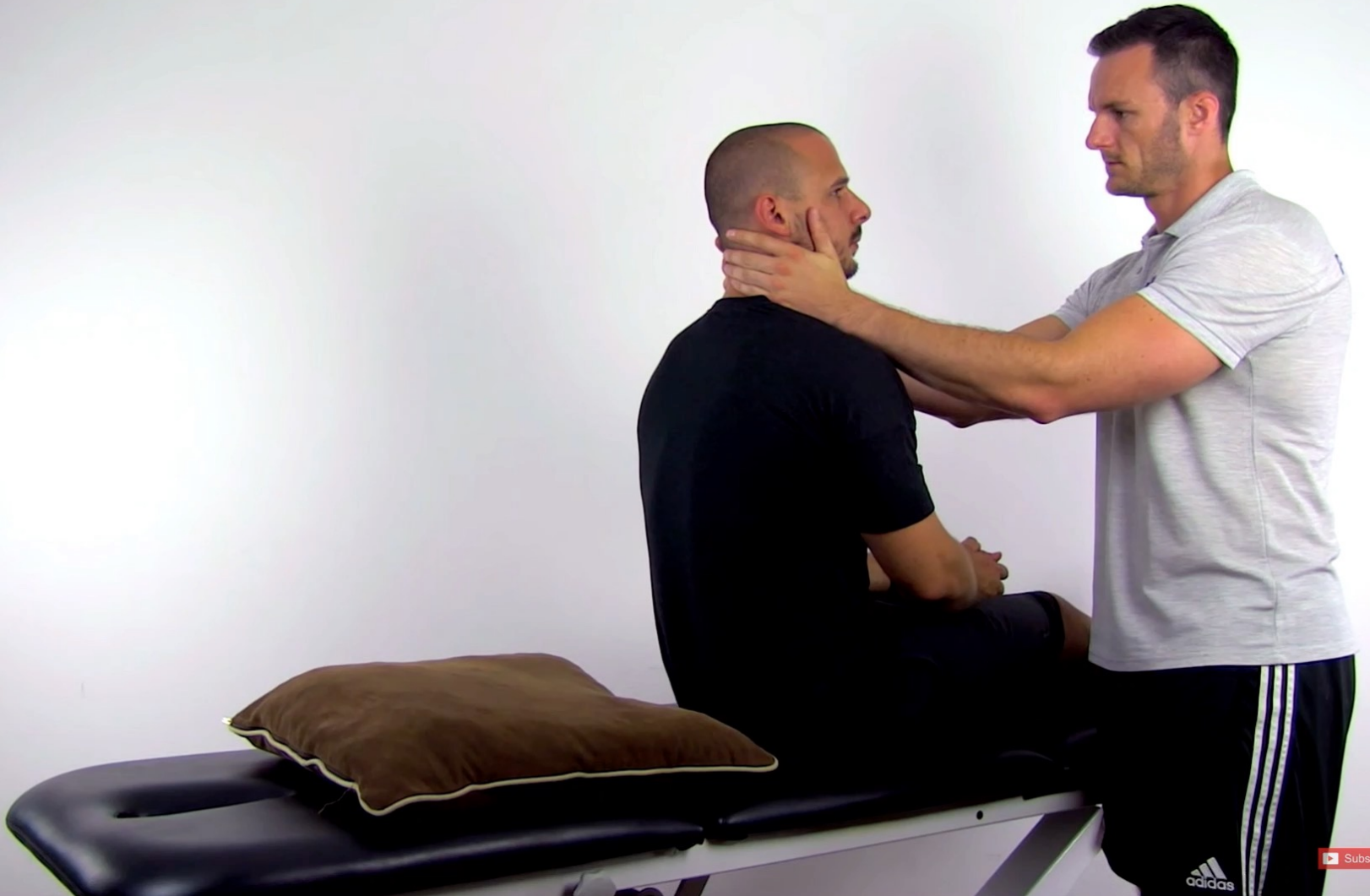# RINNE

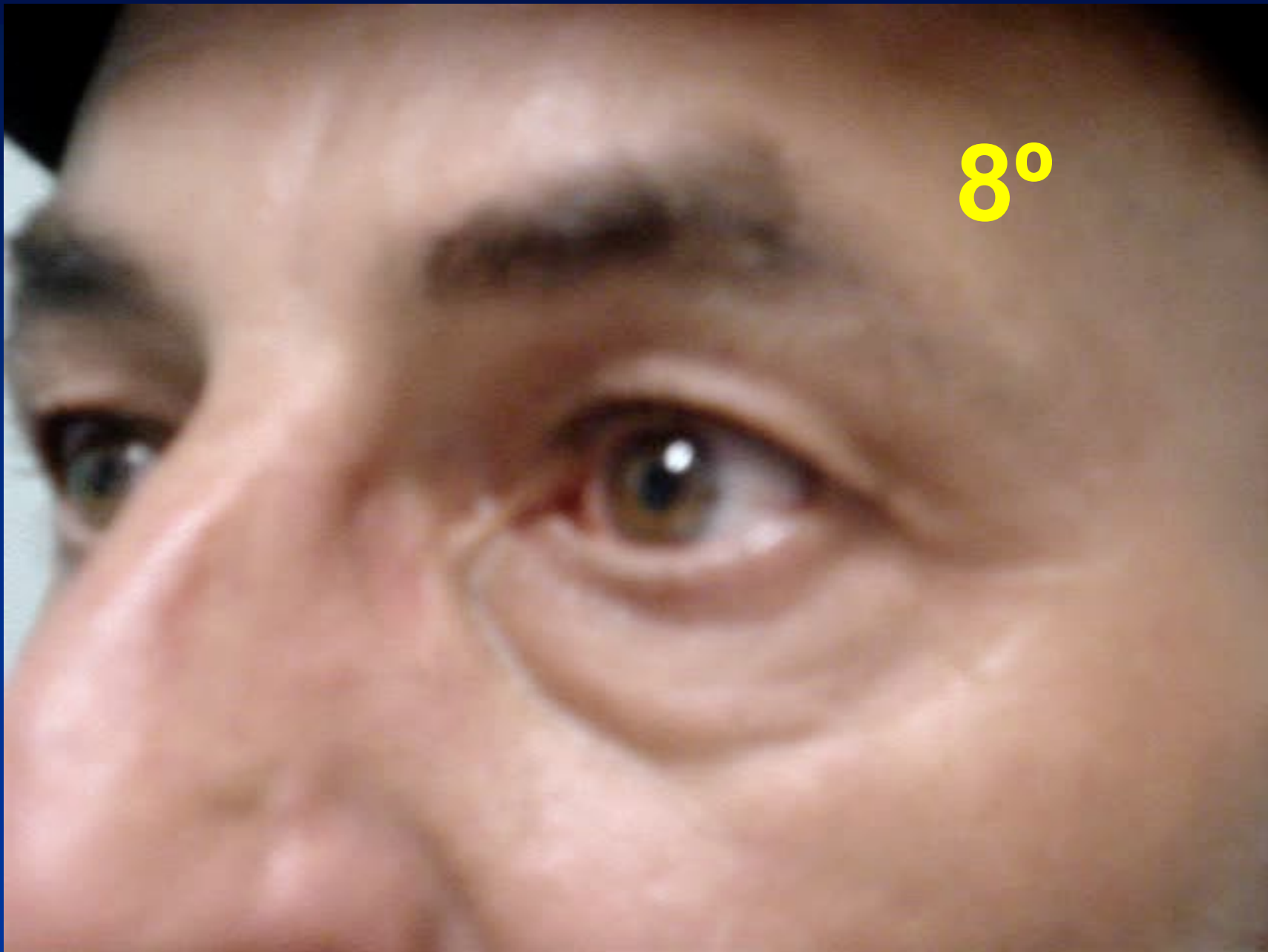CA > CO





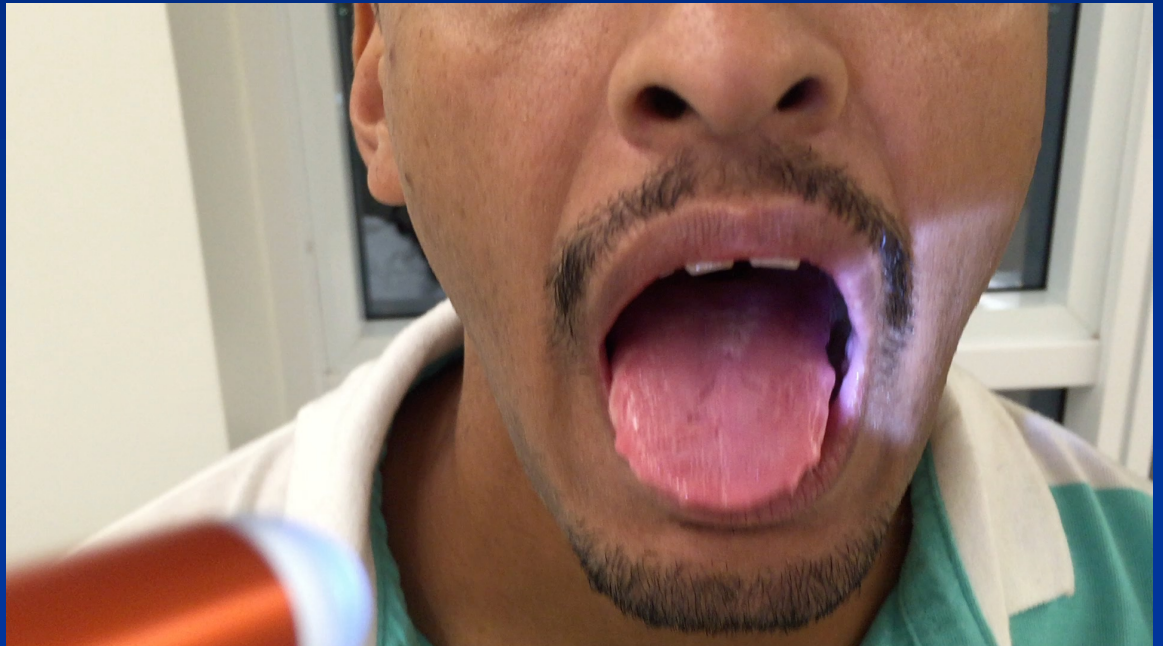
# Dix-Hallpike





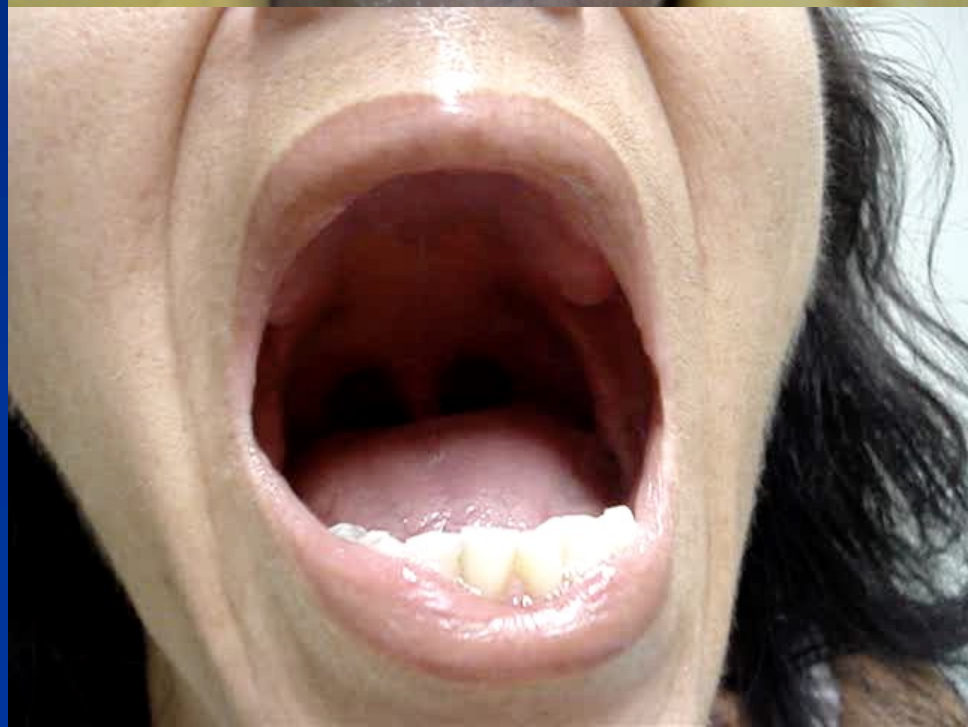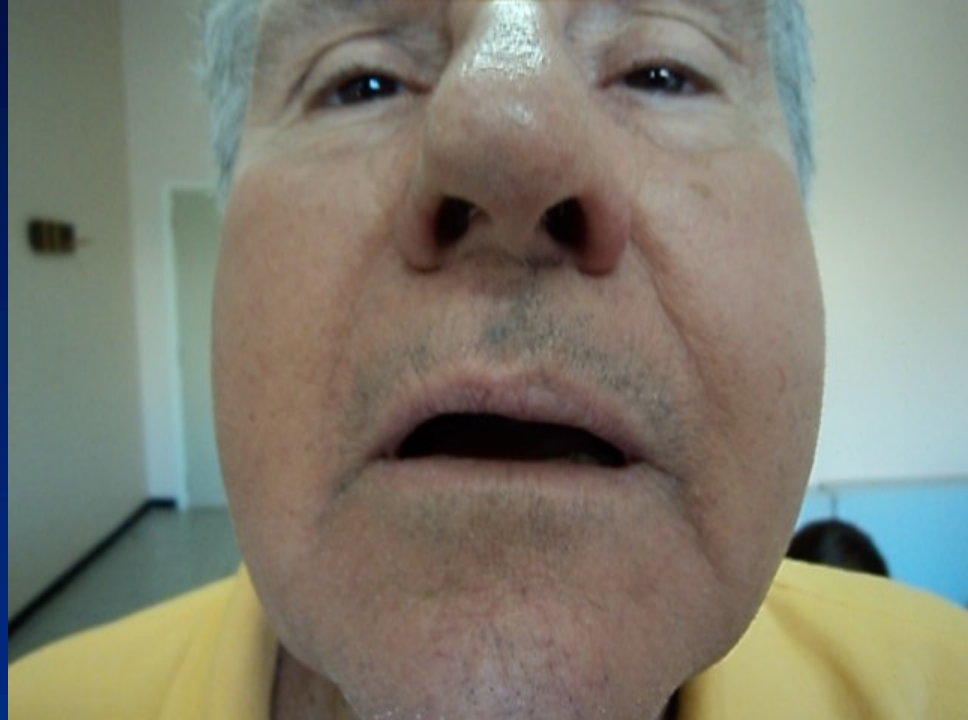8°

9° e 10°






9° e 10°





9°

10°







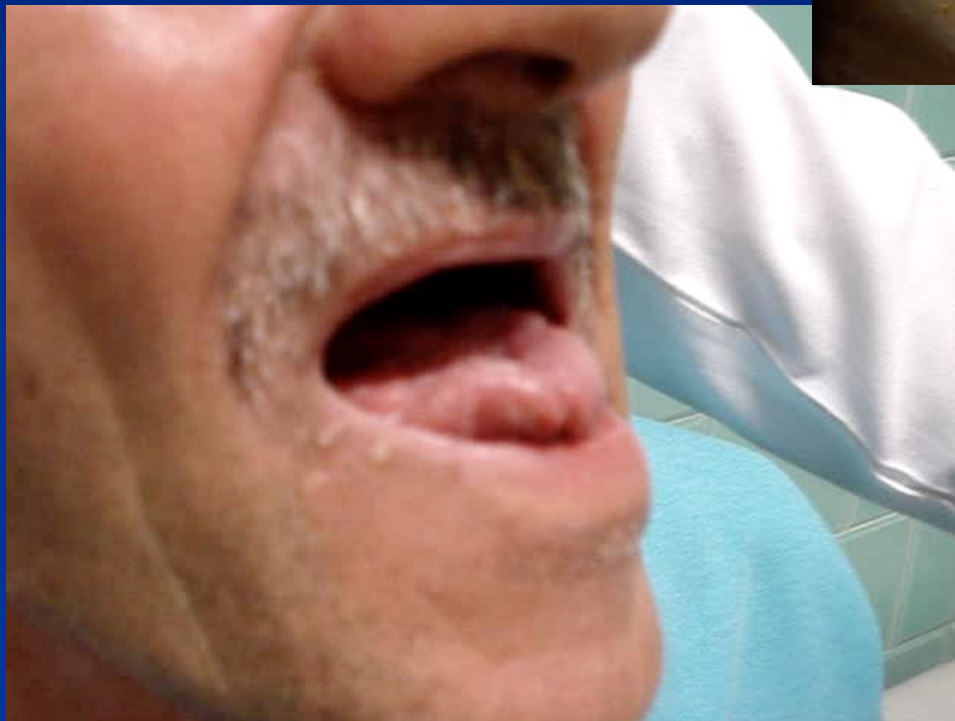
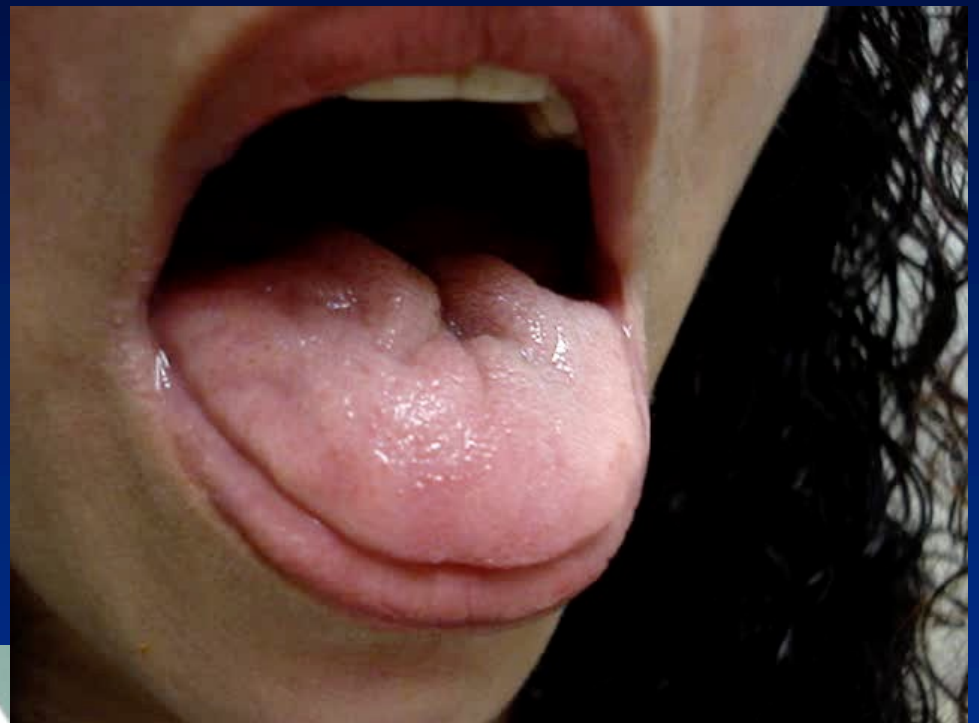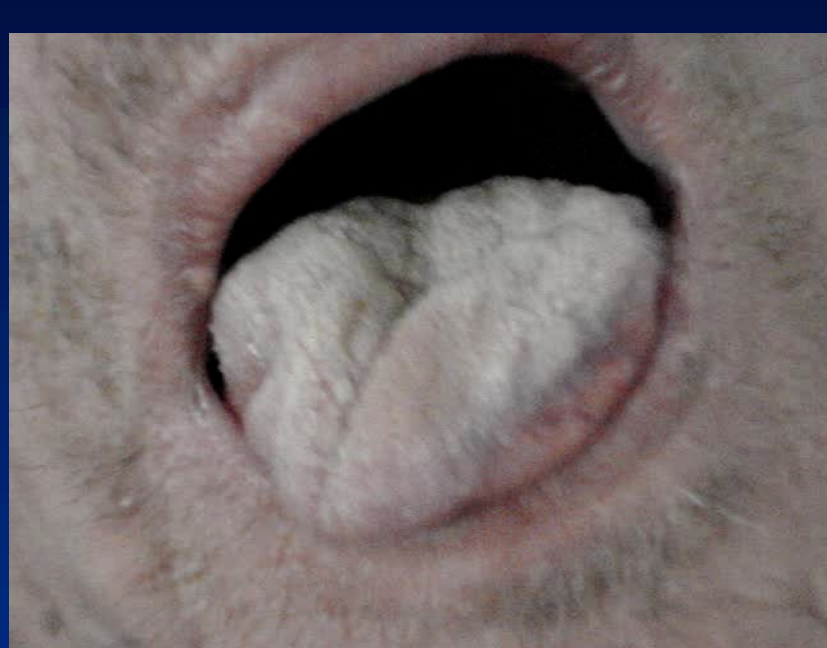7

11

“18”







12°